

A 6-Year Experience in Flat Helix Correction With a Simple Procedure

Efstathios G. Lykoudis, MD, PhD; Konstantinos Seretis, MD, MSc; Georgia-Alexandra Ch. Spyropoulou, MD, PhD

Objective: To present our 6-year experience in flat helix correction with a simple procedure. Among the many different congenital ear deformities lies the flat helix. The correction of this anomaly must be considered owing to its significance to the overall shape and appearance of the auricle.

Methods: Our surgical method is based on a geometrical approach, with radiating beveled incisions of the helical cartilage and subsequent overlapping and suturing of small triangular cartilaginous flaps. The method was applied in 15 patients over 6 years and was combined with correction of prominent ears in 9 cases.

Results: Curling of the helix was achieved in all cases. A step deformity detected in 2 initial cases led to minor technique modification. No recurrences were recorded during the follow-up period (mean follow-up, 32 months). All patients were satisfied with the aesthetic outcome.

Conclusions: The method applied is a relatively simple and reliable procedure that allows the restoration of the curvilinear shape of the helix. It can be performed under local anesthesia (along with any other procedure that a prominent ear may require), causes no visible scars, and delivers consistently effective results.

Arch Facial Plast Surg. 2011;13(3):168-172

CONGENITAL EAR DEFORMITIES are common anomalies of the head, often requiring surgical correction for both aesthetic and psychological reasons. Since the first otoplasty was performed by Dieffenbach¹ in 1845, various surgical techniques have been developed, and numerous refinements have been proposed for the correction of ear deformities.²

Prominent ears are by far the most common auricular malformation. However, many other deformities, such as constricted ears, macrotia, helical rim deformities, and others have been reported in the literature.^{2,3} Variations of the helix 3-dimensional shape, though rare, need specific consideration owing to the significance of the helix in the overall shape and appearance of the auricle. Ducourtioux⁴ first reported congenital absence of the helix, associated often with the Darwin tubercle. North and Broadbent⁵ first used the term *flat helix deformity* to describe the spatulate projection of the ear without a helical curl (**Figure 1**). This deformity, associated with the third crus of the antihelix, is also present in the Stahl or Satyr ear deformity.^{5,6}

Flat helix is a rather underestimated entity; consequently, reports that deal with its correction are scarce. The aim of this

study is to present our 6-year experience with flat helix correction with the use of a simple technique.

METHODS

We treated 15 patients (6 men and 9 women) with flat or partially folded helices as outpatients since 2004. The mean patient age was 22 years (age range, 16-36 years). In all cases but 1, the deformity was bilateral, and in 9 patients, prominent ears also existed.

Under local anesthesia (lidocaine, 2%, with adrenaline at 1:200 000), the posterior auricular approach was applied. In this approach, an incision from the upper pole of the ear to the middle of concha is performed. Should prominent ears coexist with flat helix, the incision is extended to the inferior limit of concha, so that an otoplasty can be performed. Complete degloving of the skin and soft tissue covering the helix is performed until the antihelix is exposed (**Figure 2**). Afterwards, 3 to 5 radiating incisions 5 to 10 mm long and 5 to 10 mm apart from each other are placed at the helical rim, pointing to the center of the scapha. Oblique rather than perpendicular cutting of the cartilage is performed to ensure beveled cartilage surfaces and thus to avoid step-off deformity when the cartilage is resutured (**Figure 3**). Attention is paid to limit the incisions within the helix itself to prevent violation of the scapha or the crura antihelices.

Author Affiliations:

Department of Plastic Surgery,
Ioannina University School of
Medicine, Ioannina, Greece.

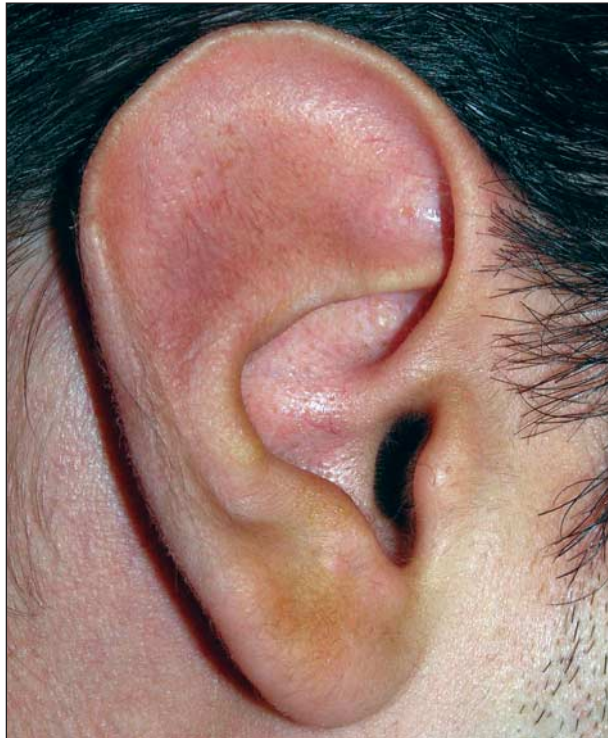

Figure 1. Typical appearance of flat helix deformity.

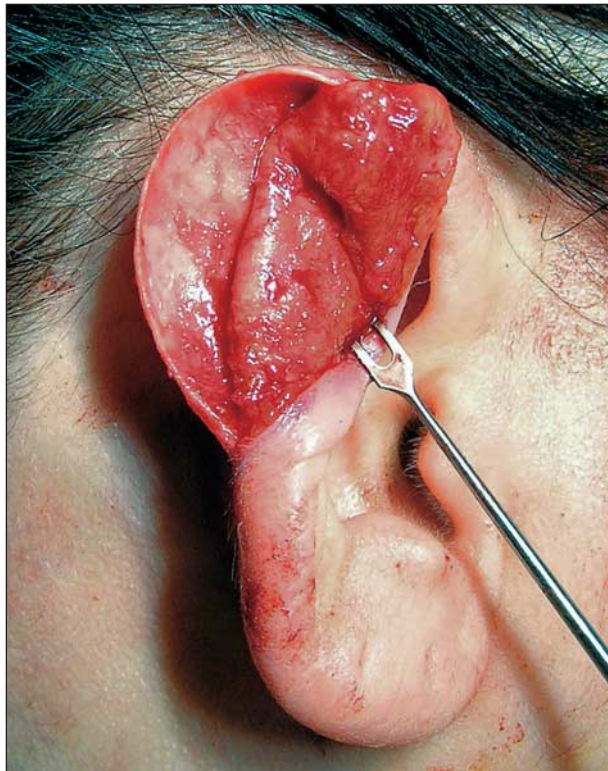


Figure 2. Exposure of helix cartilage.

The free cartilage edges are advanced, overlapping each other, and thus small triangular cartilaginous flaps are created (Figure 4) and sutured together smoothly with horizontal mattress sutures of nonabsorbable Prolene 5/0 or 6/0 (Ethicon Inc, Somerville, New Jersey) (Figure 5A). By varying the amount of overlapping cartilage and the length of the incisions, we can

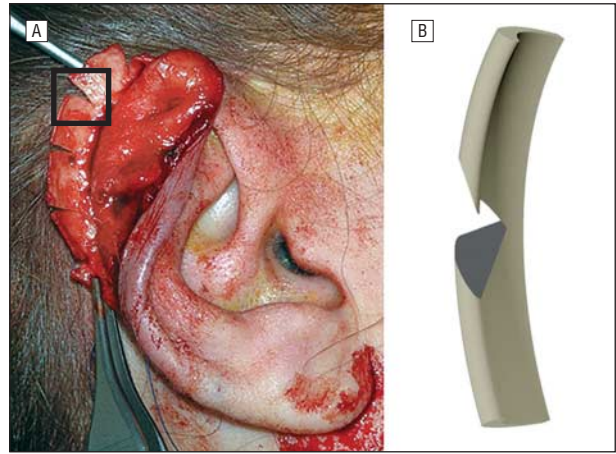


Figure 3. Demonstrated technique. A, Radiating incisions of helix cartilage. B, Line drawing magnification of the cartilage incision in the frame in panel A. Oblique cutting of the cartilage is performed using "beveled technique" to avoid step-off deformity when resuturing the cartilage.

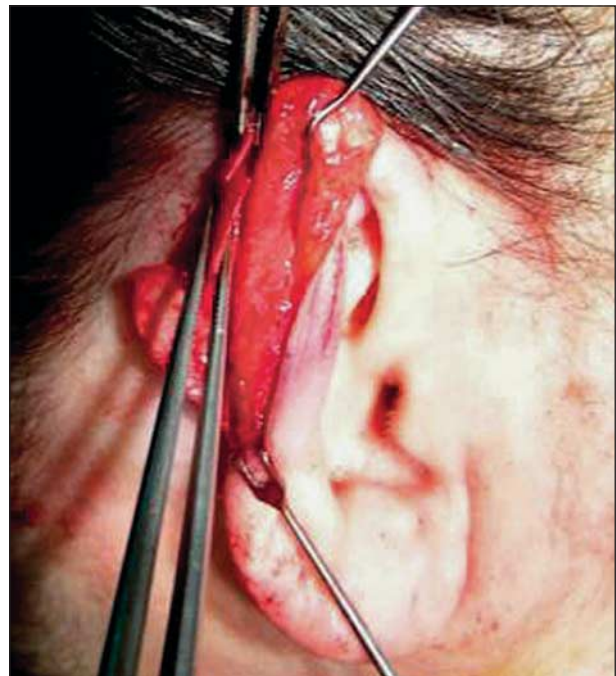


Figure 4. Cartilaginous flaps overlapping test.

finely tune the desired helical curl. If any irregularity of the newly formed helical rim is identified, this can be easily trimmed. The skin flap is then redraped over the cartilage and closed in a single layer with 5/0 absorbable suture (Figure 5B). A nonstick dressing is placed over the posterior suture line followed by gauze pads. A splint of fluffed gauze and paraffin oil is applied at the anterior surface of the newly formed helix, and a head wrap keeps all dressings in position.

RESULTS

The early postoperative period was uneventful in all patients. Mild pain, especially during the first postoperative day, was a common complaint but subsided with minimal use of medication. The compression dressing was maintained for 1 week to prevent injury, hematoma, and excessive edema forma-

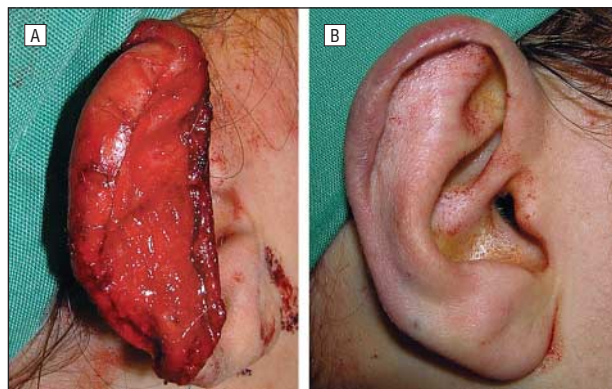


Figure 5. Appearance of the corrected helical cartilage following suturing of cartilaginous flaps (A) and immediate postoperative appearance of the corrected helix (B).

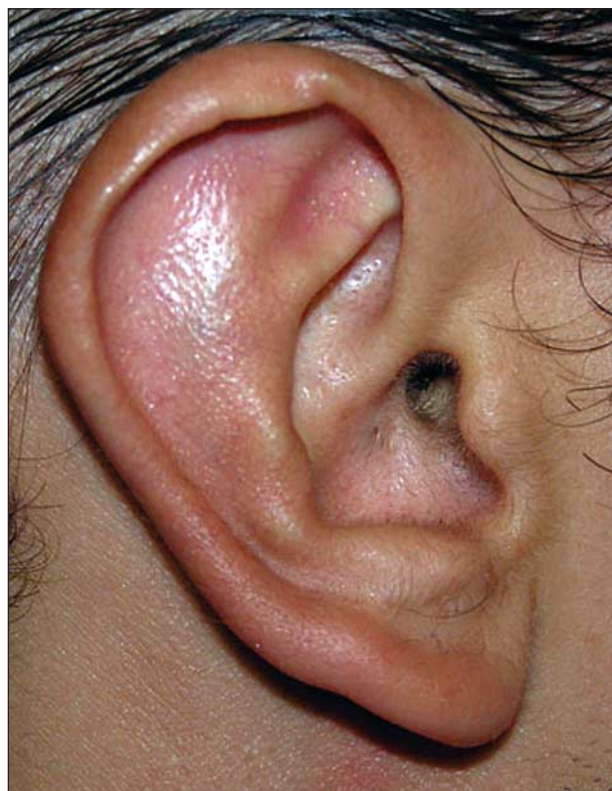

Figure 6. Step deformity following flat helix correction in one of our first cases.

tion. A step deformity (**Figure 6**), noticed in 2 of the first 4 cases, led to minor technique modification. The incisions of the cartilage were beveled to make the surface of the helix even at the suture line. No recurrences were noted during the regular follow-up period, which ranged from 8 to 66 months (mean follow-up, 32 months) (**Figure 7**). All patients were satisfied with the final aesthetic outcome, which was not affected by the concomitant prominent ear correction (**Figure 8** and **Figure 9**).

COMMENT

Although helix is significant to the overall shape and appearance of the auricle, relatively little attention has been

paid to its deformities. The Darwin tubercle presents a prominence of the helix at the outer border of the upper pole, which requires attention only if unduly prominent.⁷ On the other hand, the Stahl ear and flat helix substantially detract from the natural appearance of the helix and disrupt the harmony of the other surrounding subunits of the ear.

Stahl ear is mainly characterized by crus antihelices trifurcation, which results in posterosuperior deformation and flattening of the helical rim.^{8,9} However, the surgical techniques applied in Stahl ear correction (eg, posterior scoring and mattress suturing of the helical cartilage, full- or partial-thickness wedge excision of the deformed helical rim, cartilage graft placement) do not focus exclusively on flat helix correction.⁹⁻¹²

Reports focusing on flat helix correction are indeed very few. Ducourtioux⁴ first reported on flat helix correction, proposing 3 small cartilaginous wedge excisions, subsequent plication of the helical rim flaps, and suturing together with nonabsorbable sutures.⁴ Nevertheless, the term *flat helix* in English-language literature was introduced by North and Broadbent,⁵ who suggested the removal of a large, full-thickness wedge from the helix and reapproximation of the cartilage edges. Maurice and Eisbach¹³ refined this technique, proposing the removal of several small composite wedges of skin and cartilage without extending further than the helix. The width of the wedges varied from 5 to 10 mm, depending on the severity of the deformity.

The technique reported herein further refines the technique, introducing the concept of helical cartilage incisions, creation of cartilaginous flaps that are advanced and overlapped on each other, and skin redraping over the cartilage. To our knowledge, this is the first reported series of flat helix corrections with long-term follow-up.

Our technique is based on a geometrical approach, which permits subtle adjustments according to the severity of the deformity and the desired helical curling. The number and length of radiating helical cartilage incisions, the interval between the incisions, and the amount of overlapping of the cartilaginous flaps are the factors to consider for optimum flat helix correction. In fact, the helical curling created is proportionally increased by any of these factors. Trimming of the newly formed helix can also be performed, if necessary, to obtain a smooth helical rim. In our experience, this method has a short learning curve and can be performed together with prominent ear correction, as it was, successfully, in 9 of our cases. Moreover, there are no additional visible scars, apart from that created in every otoplasty, in contrast to the techniques of North and Broadbent⁵ and Maurice and Eisbach.¹³ Consequently, a natural overhanging of the helix along with a curvilinear shape and a normal-looking helical rim in the correct position can be created.

Another point to stress is that the cartilage incisions should not extend further than the helix itself to avoid violation of the scapha or the crura antihelices. Moreover, the amount of cartilage overlapping should

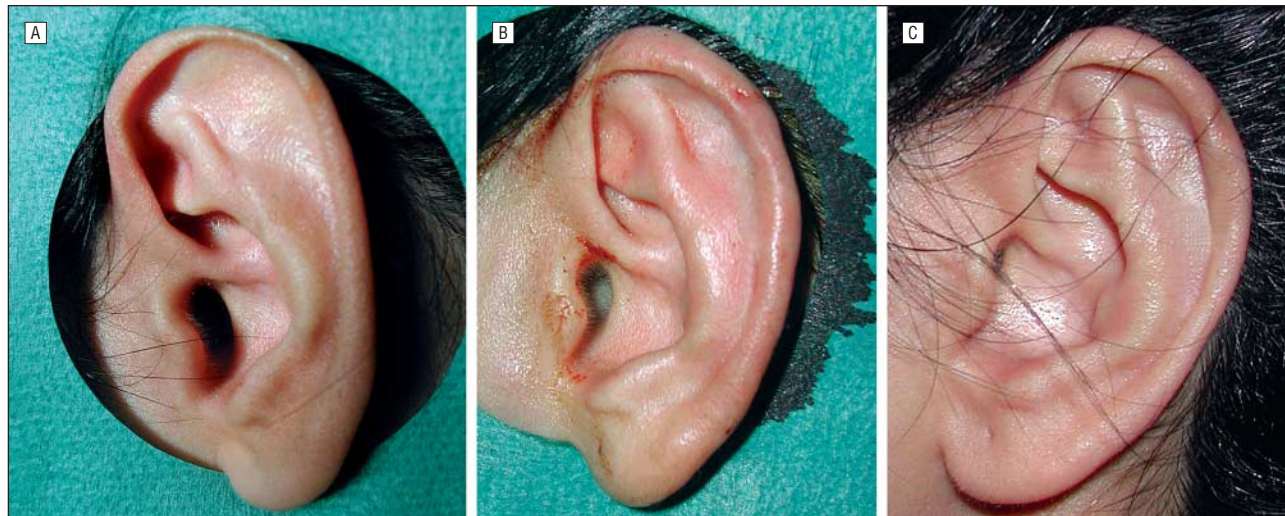


Figure 7. Appearance of the helix just prior to surgery (A), immediately after surgery (B), and 3 years after surgery (C).

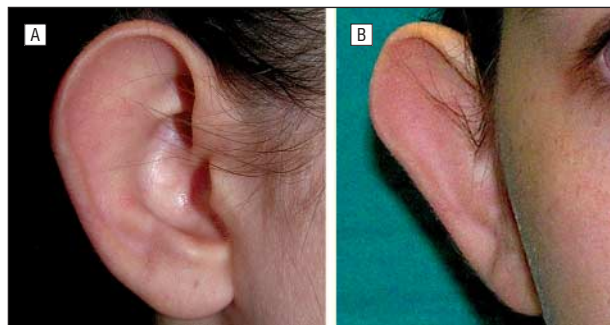


Figure 8. Coexistence of prominent ear and flat helix deformities prior to correction in lateral view (A) and anterior view (B).

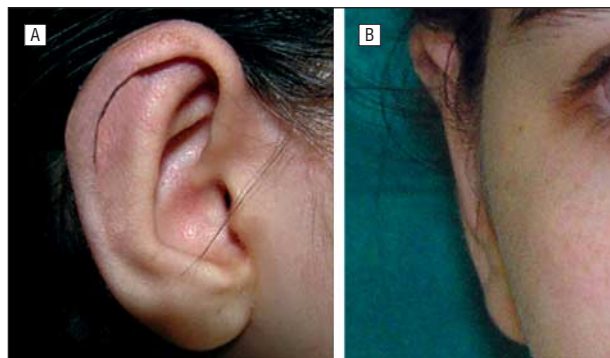


Figure 9. Simultaneous correction of prominent ear and flat helix deformities in postoperative lateral (A) and anterior (B) views.

not be excessive because if it is, a cupped appearance of the helical rim tends to result. The step-off deformity observed in our initial cases is avoided by performing oblique cartilage cutting, which ensures beveled cartilage edges. Thus, a smooth and even overlapping of the cartilaginous flaps is ensured. It is noteworthy that the skin thickness affects the final outcome, since even minor cartilage irregularities are visible when covered by thin skin. Most importantly, neither recurrences nor any significant complications have been reported over a 6-year follow-up period.

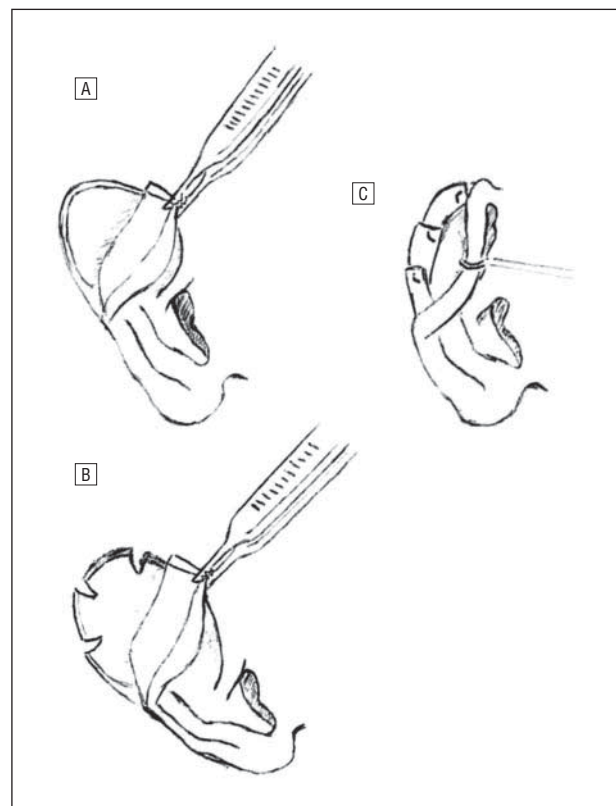


Figure 10. Line drawing showing the basic steps of the suggested technique. A, Exposure of the helical cartilage. B, Radiating incisions of the cartilage. C, Suturing of the advanced cartilaginous flaps.

In conclusion, a flat helix constitutes an auricular malformation often overlooked. It can be easily corrected with the proposed technique (depicted in brief in **Figure 10**), which is simple and provides consistently effective long-term results. A regular otoplasty procedure for prominent ears, if necessary, can be simultaneously performed.

Accepted for Publication: August 21, 2010.

Correspondence: Efstathios G. Lykoudis, MD, PhD, Department of Plastic Surgery, Ioannina University School of Medicine, University Campus, 45110 Ioannina, Greece (elykoudi@cc.uoi.gr).

Author Contributions: *Study concept and design:* Lykoudis and Spyropoulou. *Acquisition of data:* Lykoudis and Seretis. *Analysis and interpretation of data:* Lykoudis and Seretis. *Drafting of the manuscript:* Lykoudis, Seretis, and Spyropoulou. *Critical revision of the manuscript for important intellectual content:* Lykoudis and Seretis. *Statistical analysis:* Lykoudis. *Obtained funding:* Lykoudis. *Administrative, technical, and material support:* Lykoudis. *Study supervision:* Lykoudis.

Financial Disclosure: None reported.

Previous Presentations: This study was presented in part at the Seventh Hellenic Congress of Plastic Reconstructive and Aesthetic Surgery; October 28, 2005; Loutraki, Greece; and at the Fourteenth International Congress of the International Confederation for Plastic Reconstructive and Aesthetic Surgery; June 28, 2007; Berlin, Germany.

REFERENCES

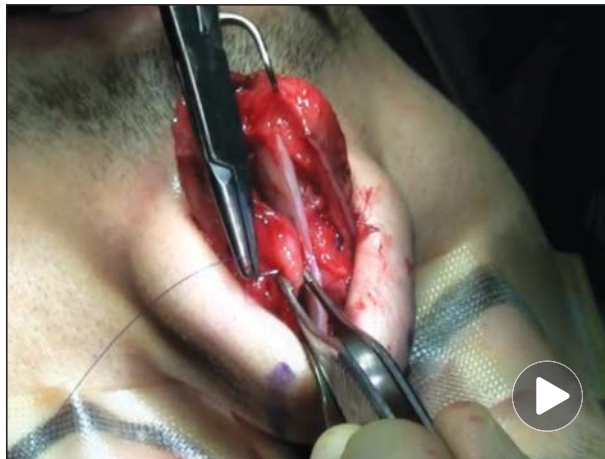1. Dieffenbach JE. *Die operative Chirurgie*. Leipzig, Germany: FA Brockhause; 1845.
2. Janis JE, Rohrich RJ, Gutowski KA. Otoplasty. *Plast Reconstr Surg*. 2005;115(4):60e-72e.
3. Tanzer RC. The constricted (cup and lop) ear. *Plast Reconstr Surg*. 1975;55(4):406-415.
4. Ducourtioux JL. A simple procedure for surgical correction of a congenitally absent helix. *Ann Chir Plast*. 1971;16(1):60-62.
5. North JF, Broadbent RG. Correcting the flat helix. *Br J Plast Surg*. 1977;30(4):310-312.
6. Fischl RA. The third crus of the anthelix and another minor anomaly of the external ear. *Plast Reconstr Surg*. 1976;58(2):192-195.
7. Elliot RA. Otoplasty. In: Regnault P, Daniel RK, eds. *Aesthetic Plastic Surgery, Principles and Techniques*. Boston, MA: Little Brown & Co; 1984:245-274.
8. Ferraro GA, Perrotta A, Rossano F, D'Andrea F. Stahl syndrome in clinical practice. *Aesthetic Plast Surg*. 2006;30(3):348-349, discussion 350.
9. Becker OJ. Correction of the protruding deformed ear. *Br J Plast Surg*. 1952;5(3):187-196.
10. Furukawa M, Mizutani Z, Hamada T. A simple operative procedure for the treatment of Stahl's ear. *Br J Plast Surg*. 1985;38(4):544-545.
11. Ono I, Gunji H, Tateshita T. An operation for Stahl's ear. *Br J Plast Surg*. 1996;49(8):564-567.
12. Kaplan HM, Hudson DA. A novel surgical method of repair for Stahl's ear: a case report and review of current treatment modalities. *Plast Reconstr Surg*. 1999;103(2):566-569.
13. Maurice PF, Eisbach KJ. Aesthetic otoplasty: wedge excision of a flattened helix to create a helical curl. *Arch Facial Plast Surg*. 2005;7(3):195-197.

Techniques in Facial Plastic Surgery

The Autospreader Flap in Reduction Rhinoplasty

Jon-Paul Pepper, MD; Shan R. Baker, MD

We describe a novel technique whereby the dorsal aspects of the upper lateral cartilages are infolded and sutured to the nasal septum as a component of reduction rhinoplasty. This maneuver provides a cantilever-like effect on the internal nasal valve while simultaneously achieving a smooth, even contour over the nasal dorsum. Visit <http://www.archfacial.com> to view a video demonstrating this technique.



Legend. The autospreader flap in reduction rhinoplasty.

Author Affiliations: Department of Otolaryngology–Head and Neck Surgery, University of Michigan, Alfred Taubman Health Care Center, Ann Arbor.